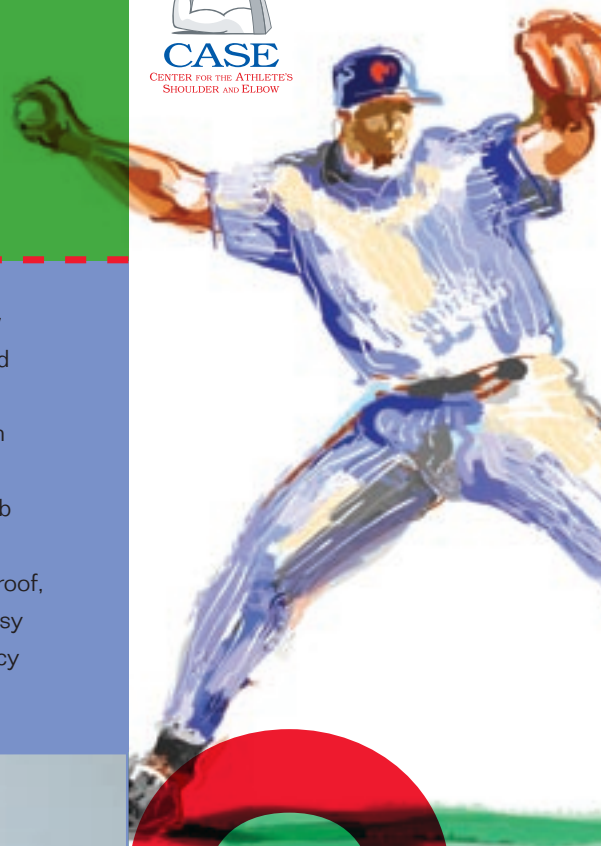


Center for the Athlete's Shoulder and Elbow Opens Its Doors



What do you get when you combine three well known orthopedic surgeons that are fellowship trained shoulder and elbow experts? The answer is "CASE," a center that is home to elite athletes from all over the Midwest and throughout the United States.

CASE was the idea of nationally recognized shoulder and elbow expert Dr. George Paletta. Dr. Paletta joined Dr. Lyndon Gross and Dr. Mark Miller at The Orthopedic Center of St. Louis to create a specialty center

that will treat complex shoulder and elbow problems. CASE is located in Chesterfield at the new state-of-the-art facility inside The Orthopedic Center of St. Louis, which also houses Imaging Partners MRI facility, Timberlake Surgery Center and PRORehab Sports Physical Therapy. With all sports medicine team members under the same roof, recreational athletes, elite athletes and busy professionals will benefit from the efficiency and convenience.

MEET THE SURGEONS

Dr. George Paletta is the leading authority in the St. Louis area on the treatment of upper extremity problems. His reputation for patient care, surgical skills and research has earned him St. Louis "Top Doctor" honors. After a distinguished lacrosse career at Holy Cross, he trained at the Hospital of Special Surgery, NY, and performed a sports medicine fellowship at The Cleveland Clinic. He went on to be the associate team physician for the New York Mets, team physician for the St. Louis Rams and medical director/head team physician for the St. Louis Cardinals.

Dr. Lyndon Gross is a team physician for the St. Louis Cardinals and Saint Louis University Billikens. He serves as an assistant professor at SLU Department of Orthopedic Surgery. He went to college at Cornell University where he played safety on the football team. He then went on to perform his orthopedic residency at the University of Pittsburgh Medical Center. He was selected to perform a sports medicine fellowship at the American Sports Medicine Institute with Dr. James Andrews and Dr. William Clancy, two pioneers in the sports medicine field.

Dr. Mark Miller is recognized as one of



Dr. George Paletta, Dr. Lyndon Gross, Dr. Mark Miller

the leading shoulder experts in the region. He performed consecutive fellowships in sports medicine and shoulder surgery. First, with Dr. Louis Bigliani in New York, then with Dr. James Andrews and Dr. William Clancy in Birmingham, AL. He was a pitcher in college and went on to play minor league baseball before attending medical school and serving his orthopedic residency at the University of North Carolina.

All three of the orthopedic surgeons at CASE have an extensive background in the treatment of complex shoulder and elbow cases. **If you would like to refer a patient to CASE, please call (636) 532-CASE, or to schedule an appointment, (314) 336-2555.**

CASE

CENTER FOR
THE ATHLETE'S
SHOULDER &
ELBOW

MRI and MRI Arthrography In the Diagnosis of Shoulder Pathology

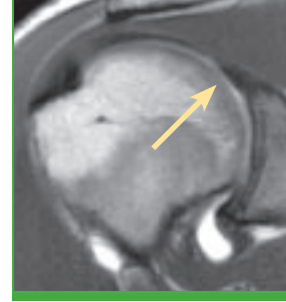
LYNDON B. GROSS, MD, PH.D.

MRI imaging of the shoulder has been used for years to provide a comprehensive evaluation of the shoulder for a wide spectrum of pathology of the shoulder. Its unique capability to provide multiplanar imaging in the differentiation of soft tissues of the shoulder has allowed it to surpass other modalities such as CT and arthrography. Improvement in coil design and imaging techniques have made MRI imaging a powerful modality for noninvasive evaluation of shoulder pathology and one of the most important tools for the diagnosis of shoulder pathology.

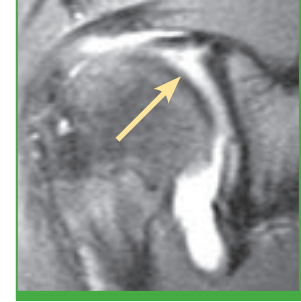
MRI Imaging is used for the shoulder to evaluate the rotator cuff, labrum and capsular structures. Accuracy of MRI imaging is primarily based on the differences between normal and pathologic tissue, such as increased signal intensity, attenuation and irregularities in the pathologic tissues as compared to normal tissues. For certain patterns of pathology such as full thickness rotator cuff tears the sensitivity of conventional MRI imaging for detecting complete tears is very high (75%-90%).

Other patterns of pathology, such as partial rotator cuff tears and labral tears show less sensitivity for diagnosis with conventional MRI imaging (20% -71% and 44% -95%, respectively). This may be related to the lack of signal abnormality in the pathologic tissue or to the fact that intra-articular structures of the shoulder are not well depicted when insufficient fluid is present to outline their contour.

MRI arthrography has been increasingly used for the evaluation of rotator cuff, labrum, and capsular structures. It is known that intra-articular structures and abnormalities are better visualized in shoulders that have effusions and MRI arthrography exploits the natural advantage gained by joint effusions. MRI arthrography increases the sensitivity for diagnosis of full thickness rotator cuff tears, approaching 100% sensitivity. Although the reproducibility of both conventional MRI and MRI arthrography imaging is similar for rotator cuff tears, MRI arthrography also allows more accurate morphologic



Normal Labrum



Labral Tear

classification of the torn tendon than conventional MRI imaging. The diagnosis of partial rotator cuff tears is improved with MRI arthrography, with the visualization of the irregular contour of the cuff enhanced by contrast. MRI arthrography allows improved visualization of subtle labral, cartilage and ligamentous abnormalities. This is an important factor when dealing with high performance athletes who usually have subtle finding with regards to rotator cuff, or labral pathology.

MRI arthrography extends the capabilities of conventional MRI imaging in the diagnosis of rotator cuff and labral pathology. Although MRI arthrography is more expensive than conventional MRI imaging, it has greater accuracy and provides significant higher cost-effectiveness based on the improved diagnostic efficiency.

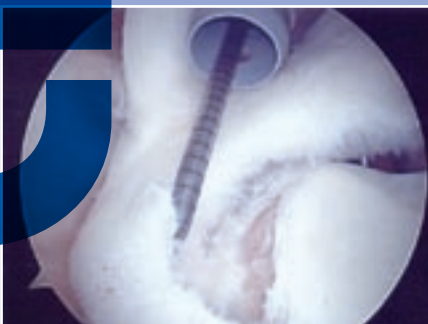
CASE STUDY

MARK D. MILLER, MD

Playing with pain is a trait worn like a badge of honor by athletes. Playing with pain is almost a necessity in many of our contact sports. But when is playing with pain no longer an asset but a red flag signaling for medical evaluation and treatment?

Consider J.C, a 15-year-old sophomore multi-sport athlete who began having problems with his dominant right shoulder in October. He was a defensive lineman who was cut block, causing him to fall on his outstretched right arm. He felt shooting pain deep in his shoulder, but was able to continue playing. He was able to tolerate the popping through the

Labrum separated from Glenoid



remainder of the season. The popping and pain progressed when he began wrestling to the point when he could no longer play with the pain.

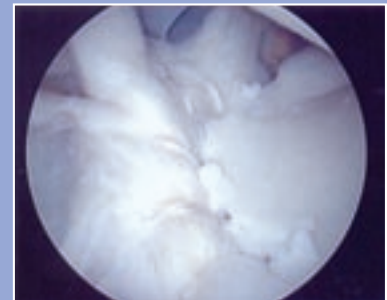
His orthopedic evaluation in late December

revealed signs and symptoms consistent with a labral/SLAP tear. This was confirmed by an MRI arthrogram and surgery was recommended. The arthroscopy revealed near circumferential labral damage that required a 5 anchor repair. He also had a very substantial Hill Sachs articular defect on the humeral head consistent with more instability than the patient reported.

Question? How much damage could have been avoided with an evaluation in October?

Lesson: Popping and deep shoulder pain in a young athlete often means subtle instability, labral pathology, even articular cartilage damage. One should listen for the key phrases, "popping," "deep in my shoulder," "giving out." **EVALUATE EARLY!**

Repaired Labrum



Labral Tears

GEORGE A. PALETTA, JR., MD

Labral injuries are common in a wide variety of athletes, especially overhead or throwing sports participants. However, labral tears include a wide range of differing injuries with different treatment algorithms and different time frames for return to sport. This article will provide a review of labral injuries, their causes, and treatments.

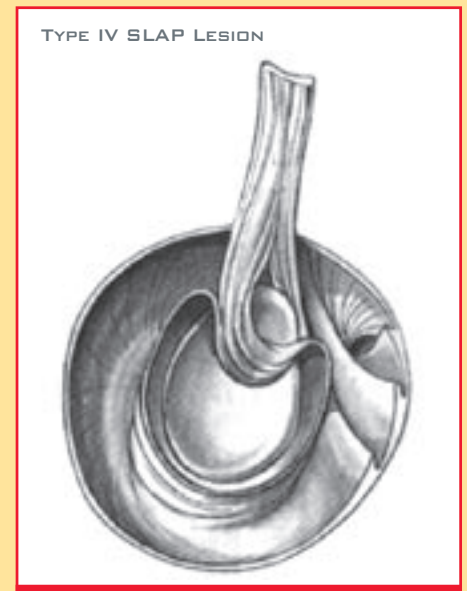
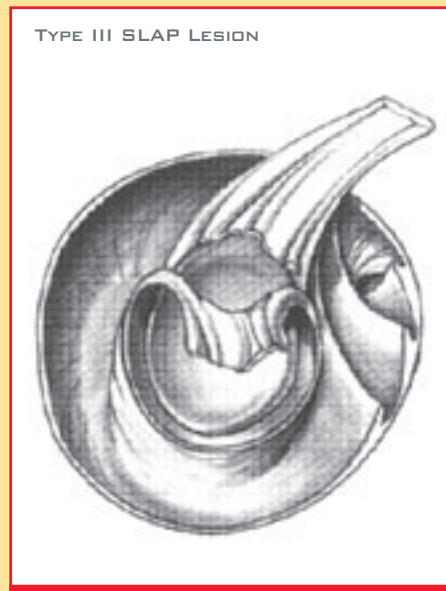
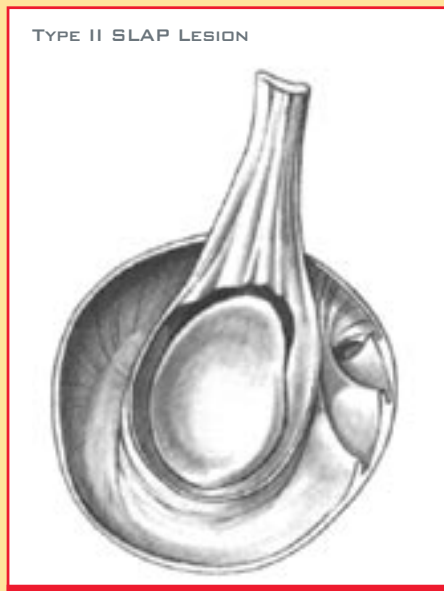The labrum is a 3-5 mm wide fibrocartilage ring or gasket surrounding the edge of the glenoid or socket of the shoulder joint. It is typically well attached to the edge of the glenoid except in the anterior superior quadrant where there is a high degree of anatomic variation. The tendon of the long head of the biceps tendon attaches to the superior aspect of the labrum

labral tears, or so-called Bankart lesions, are typically the result of traumatic anterior dislocations of the shoulder. These injuries are common in contact sport athlete such as football or hockey players. Biceps anchor injuries are known as SLAP tears. SLAP is an acronym for Superior Labrum Anterior to Posterior. This injury pattern is common in overhead athletes such as tennis and volleyball players or in throwing athletes such as baseball pitchers. The most common mechanism is repetitive trauma although SLAP tears can result from a single injury episode. Posterior superior labral tears are also most common in overhead and throwing athletes, however, they can also result from posterior instability such as a dislocation.

phase of throwing or overhead activity.

The diagnosis of a labral tear is based on the typical clinical history, careful physical exam, and appropriate imaging studies. The clinician must have a high index of suspicion in those athletes participating in at-risk sports or who give a history of recurrent instability of the shoulder. Plain x-rays of the shoulder are usually normal in athletes with labral tears. MRI scanning with intra-articular contrast (gadolinium) is the imaging study of choice. MRI arthrography has both high sensitivity and specificity for detecting labral tears.

The treatment of labral tears is usually surgical. Tears of the labrum typically represent an internal derangement of the shoulder. Non-operative treatment is rarely



at what is known as the biceps anchor. The glenohumeral ligaments also originate from the labrum as part of the capsulolabral complex. These ligaments play a crucial role in stabilizing the glenohumeral joint. The role of the labrum is to deepen the glenoid and to improve the congruence of the ball and socket design of the shoulder joint. In doing so it helps to increase stability of the glenohumeral joint.

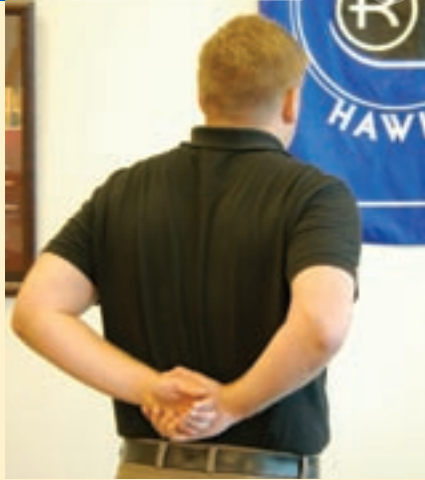Tears of the labrum can result from a wide variety of injury mechanisms and involve almost any part of the labrum. The most common sites of involvement include the anterior inferior labrum, biceps anchor, or posterior superior labrum. Anterior inferior

Most important, labral tears may not be isolated injuries and are commonly associated with other injuries or pathologic processes about the shoulder.

The classic symptoms for labral injuries will depend upon the pattern and mechanism of injury. Athletes with Bankart lesions will most often give a history of shoulder dislocation or subluxation. Athletes with SLAP tears or posterior superior labral tears will most often complain of pain with the overhead aspect of their sport such as serving in tennis, spiking in volleyball, or throwing in baseball. The typical pain complaints are of activity related pain deep within the shoulder, especially in the cocking

successful with the exception of certain posterior superior labral injuries. Surgical treatment is arthroscopic and usually performed on an outpatient basis. In cases without detachment of the labrum, debridement or shaving of the torn portion of the labrum may be sufficient. In those cases of complete tear or detachment of the labrum, arthroscopic repair with suture anchors to reattach the labrum is indicated.

Recovery from labral surgery includes a period of sling immobilization and supervised physical therapy. Although success rates are high, approaching 80-90% in most cases, the time to return to sports may be as long as 9-12 months.



JOHN TEEPE, PT

If your posterior capsule is tight, the humeral head will move superiorly and posteriorly while the shoulder is in the 90/90 position. The total ROM (IR + ER) of the shoulder needs to be the same between both shoulders. Thus, it is important to address the posterior capsule flexibility to

avoid GIRD (glenohumeral internal rotation deficit). Here are a couple of stretches that emphasize the posterior capsule. The stretches should be held for 30 seconds and performed 3-5 times/daily, especially after throwing or after strengthening of the posterior rotator cuff.

SPOTLIGHT

KEITH SANDERS, PT, MHS

STAR REHABILITATION – Creve Coeur, MO
ST. LOUIS CARDINALS – St. Louis, MO

EDUCATION – St. Louis University
MHS – Washington University

Keith specializes in the treatment of shoulder, elbow and knee injuries. He is a member of the American Society of Shoulder and Elbow Therapist. In addition to his practice with STAR Rehabilitation, he is the Physical Therapist for the St. Louis Cardinals. To refer a patient to Keith call (314) 996-3050.

